



Digital Scanning for Orthoses

It's all about positioning!

BY DOUGLAS RICHIE, DPM

Introduction

Digital scanning has gained increased popularity in the podiatric profession as an alternative to traditional negative impression casting for the fabrication of custom foot orthoses and ankle-foot orthoses. Accompanying this trend is confusion and misinformation about the accuracy of digital scanning as well as the acceptable positioning of the patient during the scanning process.

History

Custom foot orthoses and ankle-foot orthoses have traditionally been fabricated from impression casts and positive molds using plaster of Paris material. These traditional methods of custom lower extremity orthosis manufacturing are time-consuming, labor-intensive, environmentally hazardous, and require use of large amounts of consumable materials.¹

As a result of these shortcomings, digital technology has gradually replaced plaster of Paris in all aspects of custom lower extremity orthotic manufacturing. Digital scanning uses technology which can capture the three dimensional (3-D) shape of the leg, foot, and ankle.^{3,4} In addition, digital technology is now used to create a 3-D model of the foot or ankle without the need for plaster. As a result, adjustments or modifications of the digital model can be made with a computer rather than adding or removing plaster from a traditional positive cast.⁵ Finally, digital technology is now being utilized to program machines for milling of the orthosis

or for additive manufacturing with a 3D printer.^{6,8}

With change comes skepticism in our profession, and changing to new digital technology is no exception. Many still cling to the old school notion that plaster of Paris is more accurate and reliable than digital technology. On the other end of the spectrum, some practitioners assume that the magic of digital technology

in each of the studies, particularly whether the scanner required contact with the plantar surface of the foot, creating a partial or full weight-bearing condition. Newer scanners do not require contact of the foot on a footplate or mat and this appears to enhance the shape and contour of the resultant orthotic device.

Several studies showed differences in foot shape depending on posi-

Digital scanning has been shown in several studies to be as accurate as plaster of Paris impression casting to capture the shape of the foot and ankle for the fabrication of orthoses.

obviates the need for “old school” positioning of the patient in order to produce an optimal cast model.

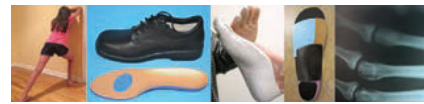Accuracy of Digital Scanning

Digital scanning has been shown in several studies to be as accurate as plaster of Paris impression casting to capture the shape of the foot and ankle for the fabrication of orthoses.⁹⁻¹³ Most of these studies focused on intra- and inter-rater reliability when comparing certain parameters of foot shape from the different casting methods. These studies show that if the same practitioner took several scans of the same foot of a patient or if several practitioners took a scan of that same patient's foot, the results would be consistent. There was variability in the type of scanner used

tion of the foot and weight-bearing by the patient. Regardless of whether a plaster cast or a digital scan is utilized, significant changes in foot shape occur when comparing neutral suspension casting vs. partial weight-bearing and full weight-bearing patient positioning. Therefore, the debate should not focus on accuracy of digital scanning vs. plaster of Paris to capture foot shape but, instead, should focus on optimal positioning of the foot for the best orthotic treatment outcome.

Contour of the shape of the foot orthosis to the anatomy of the plantar surface of the foot has been demonstrated to be a critical factor in both the comfort and efficacy of the device.¹⁴ The importance

Continued on page 74



Digital Scanning (from page 73)

of capturing the forefoot to rearfoot alignment as originally proposed by Root, et al.¹⁵ is theoretically a major factor in orthotic treatment efficacy, and this principle has been well accepted by the podiatric profession for many years.^{16,17} However, it must be emphasized that both shape and forefoot to rearfoot alignment are significantly affected by positioning the foot of the patient during the casting or scanning process.

How Does Weight-Bearing Affect the Casting Process?

In 2007, Jeff Root and this author published an article in *Podiatry Management* comparing the shapes and forefoot-to-rearfoot alignment obtained from impression casts of a single patient in three different weight-bearing conditions: 1) Neutral suspension

arch height, and calcaneal inclination were noted when comparing the three casting positions. With weight-bearing, the impression cast captured a wider heel and lower arch compared to the neutral suspension technique.

In a peer-reviewed published study, Tsung and co-workers compared the shape of plaster casts of eight adult feet taken in non-weight-bearing, semi-weight bearing and full weight-bearing conditions.¹⁹ Compared to the non-weight-bearing foot shape, the semi-weight-bearing condition produced a 6% wider heel, a 15% decrease in arch height and a 21% lowering of arch angle. With a full weight-bearing cast, compared to a non-weight-bearing

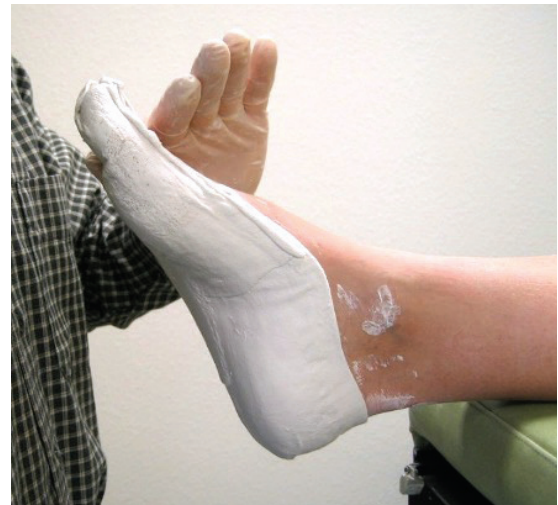

Figure 2: The neutral suspension cast: Non-weight-bearing, subtalar neutral and forefoot maximally pronated against the rearfoot.

arch in an effort to reduce excessive closed chain STJ pronation by supporting the talo-navicular unit. A semi-weight-bearing or weight-bearing cast or scan captures a pronated foot shape with the talus in a more plantarflexed (i.e., compensated) position than it would be in a non-weight-bearing, neutral suspension cast of the same foot.

Actively resisting talar adduction and plantarflexion during closed chain STJ pronation, an orthosis can reduce the range of STJ pronation and reduce pathological forces. An orthosis made from a non-weight-bearing cast or scan captures the proximal, medial arch in its un-compensated, true anatomic shape, thereby providing enhanced medial column support.

Furthermore, an impression cast or scan taken of the foot during full weight-bearing captures a lower calcaneal inclination and a distorted forefoot to rearfoot alignment. Finally, the wider heel contour of a weight-bearing cast will produce an orthosis with poor frontal plane control of the rearfoot.

Therefore, a non-weight-bearing condition of the patient allows proper capture of foot shape to produce an orthosis with optimal features to properly direct ground reaction forces for enhanced biomechanical control. Even in a non-weight-bearing condition, variations of positioning of the foot by the practitioner can have significant in-

Continued on page 76

Scanning or casting in a weight-bearing position will result in a flatter, wider foot orthosis with a lower arch compared to a non-weight-bearing cast technique.

technique, non-weight-bearing; 2) Partial weight-bearing, neutral subtalar joint position; and 3) Full weight-bearing, neutral subtalar joint position.¹⁸ We demonstrated that when a patient with a true forefoot valgus deformity was allowed to bear any weight on the foot during the casting process, the forefoot-to-rearfoot relationship changed from valgus to varus (Figure 1). Furthermore, significant changes in geometry of heel width, arch width,

ing cast, the rearfoot width increased 8%, the arch height decreased 20%, and the arch angle decreased 41%.

The lesson learned here is that scanning or casting in a weight-bearing position will result in a flatter, wider foot orthosis with a lower arch compared to a non-weight-bearing cast technique. While a functional foot orthosis is much more than an arch support, a well-designed functional orthosis must also support the proximal aspect of the medial

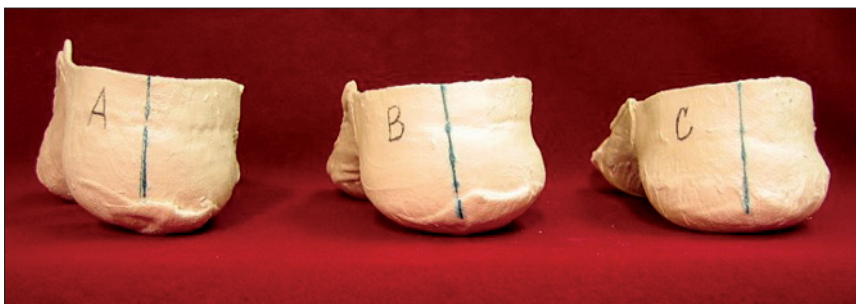
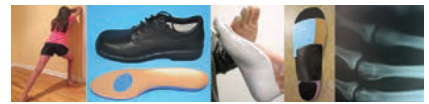
Figure 1: Forefoot to rearfoot alignment changes significantly in same patient when casted (A) Non-weight-bearing (B) Semi-weight-bearing (C) Full weight-bearing.



Digital Scanning (from page 74)

fluence on the final shape and efficacy of the custom orthosis.

Proper Position of the Patient by the Practitioner

In 1971, Root, et al. published a detailed description of the “neutral suspension casting technique” for taking a plaster of Paris impression of the foot for fabrication of custom foot orthoses.²⁰ Since that time, several authors have pointed out the challeng-

of the foot was proposed to theoretically “lock” the midtarsal joint for stability, which would assure more stable control of the custom foot orthosis during dynamic gait. This notion of osseous midtarsal joint “locking” has been challenged by several researchers.^{24,25} However, a stiffening effect across the midfoot joints is achieved with moving the subtalar joint from a pronated position to a neutral position, and this stiffening

The cornerstone of the neutral suspension casting technique is positioning the forefoot in maximal pronation against the rearfoot which is maintained in a neutral position at the subtalar joint.

76

es of reliably positioning the foot in subtalar neutral while also properly positioning the forefoot relative to the rearfoot using this neutral suspension technique.^{21,22} Notwithstanding, the neutral suspension casting technique has stood the test of time and remains the gold standard for impression casting for custom foot orthoses in the podiatric profession.^{17,23}

The cornerstone of the neutral suspension casting technique is positioning the forefoot in maximal pronation against the rearfoot which is maintained in a neutral position at the subtalar joint (Figure 2).²⁰ This positioning

mechanism of the midfoot has been verified in several studies.^{26,27}

Furthermore, pronation of the calcaneocuboid joint engages an anatomic osseous locking which provides sagittal plane stability across the midfoot during heel-rise.²⁸ Therefore, the science appears to verify why the neutral suspension casting technique, positioning a fully pronated forefoot on the rearfoot, opti-

mizes stability of the foot. It is intuitive that positioning the foot in its optimal stable position during digital scanning will provide the best model for a positive orthotic therapy outcome.

Based upon sound science and a long track record of success, it makes no sense to abandon the

essential parameters of neutral suspension casting technique when performing digital scanning for custom foot orthoses and ankle-foot orthoses. In short, a digital scan must be taken of the foot which is positioned in subtalar neutral while the forefoot is fully pronated on the rearfoot.

Simply scanning the foot “hanging in space” completely violates the core foundation of podiatric biomechanics. Furthermore, there is no chance that the fabrication laboratory can compensate or modify a scan of an improperly positioned foot. The three-dimensional changes in foot contour which occur when the foot is positioned in subtalar

Continued on page 78

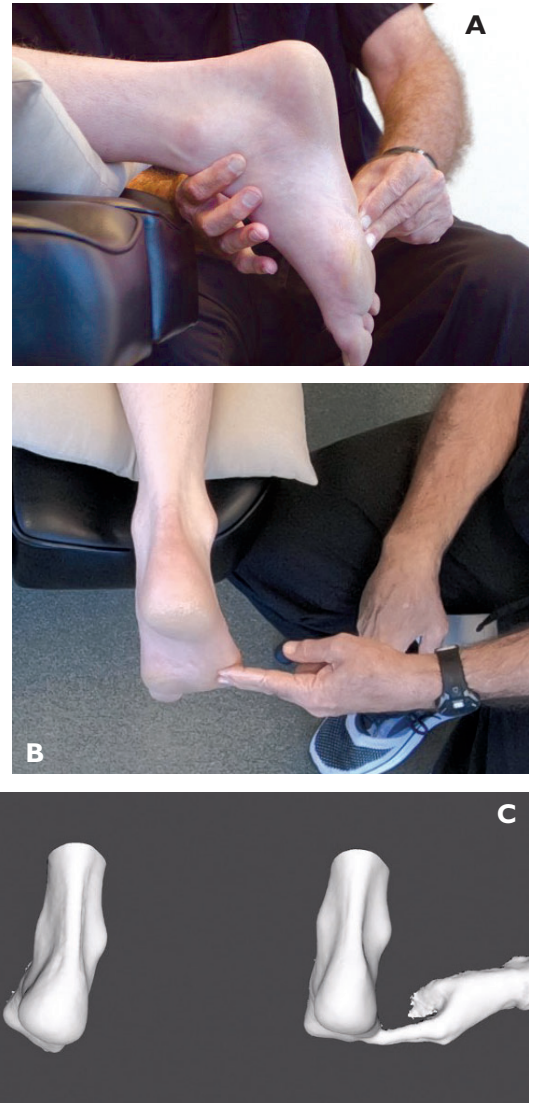


Figure 4: Digital scanning of the foot and ankle for AFO braces is performed optimally with the patient prone. (A) Palpating for subtalar neutral (B) Pronating the forefoot on the rearfoot (C) Comparison of scans showing foot hanging in space vs. proper pronation of the forefoot.

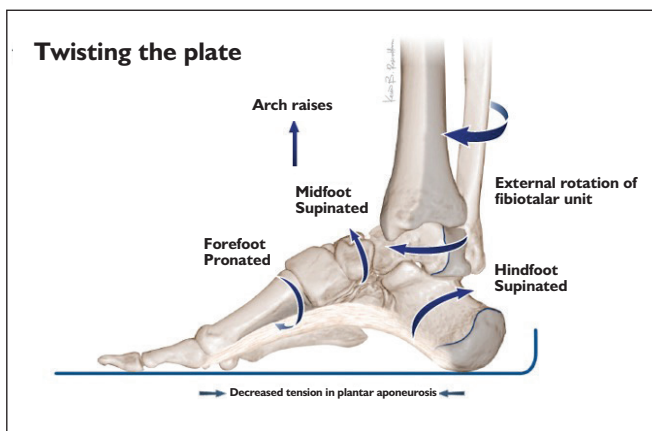


Figure 3: Twisting the plate of foot bones to resist pronation of the rearfoot: Forefoot pronation is coupled with rearfoot supination.

Digital Scanning (from page 76)

neutral while the forefoot is pronated on the rearfoot are unique to each patient's anatomy and cannot be predicted with computer modeling.

Further Reason to Pronate the Forefoot on the Rearfoot during the Casting/Scanning Procedure

Pronation of the rearfoot is coupled with supination of the forefoot during weight-bearing. This “compen-

Continued on page 79

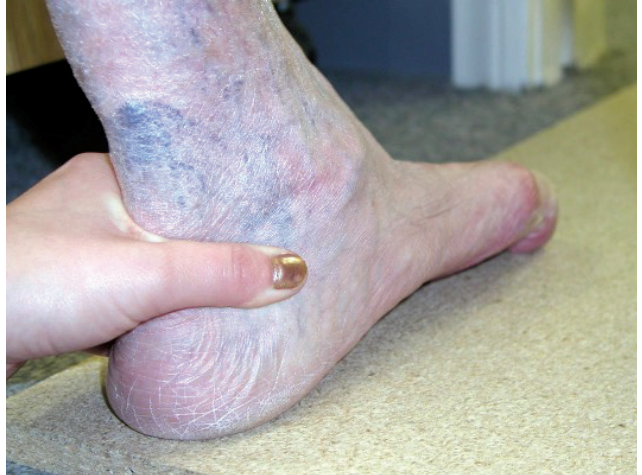

Figure 5: Forefoot supination deformity in Adult Acquired flatfoot.

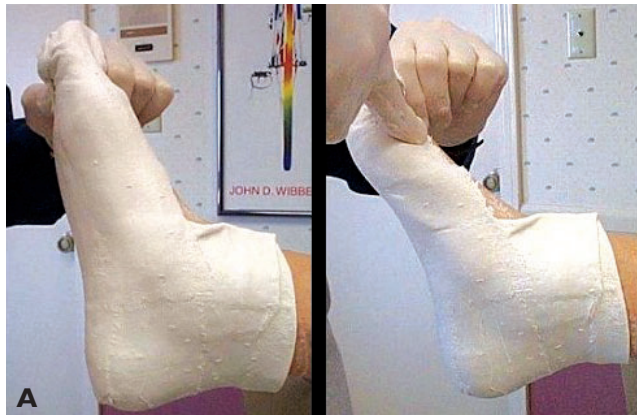

Figure 6: (A) Correcting forefoot supination deformity in Stage 2 Adult Acquired Flatfoot during impression casting. Forefoot supination (Uncorrected) Forefoot supination (Corrected). (B) Comparison of rearfoot alignment of each cast.

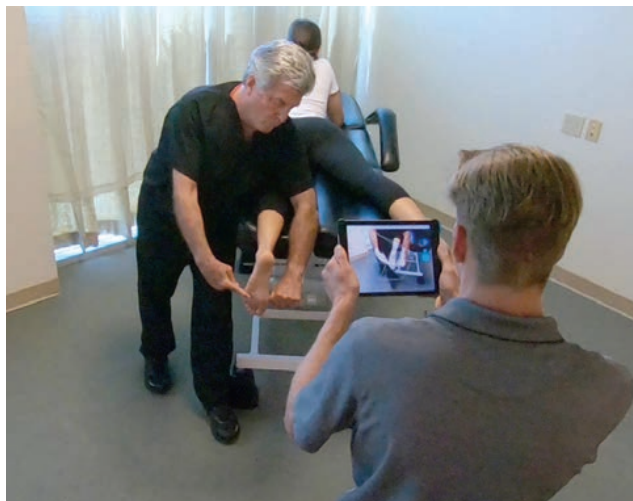

Figure 7: Reducing forefoot supinatus deformity during the digital scanning procedure. Practitioner uses two hands to pronate the forefoot on the rearfoot.

Digital Scanning (from page 78)

satory torsion” was originally described by Steindler in 1929.²⁹ Later, MacConaill and Sarrafian both described the “twisted plate” mechanism of the human foot whereby pronation of the forefoot induces supination of the rearfoot (Figure 3).^{30,31} According to this mechanism, a foot orthosis which positions the forefoot into supination will induce compensatory pronation of the rearfoot. Most feet hanging in space will demonstrate a supinated forefoot to rearfoot relationship which can be reduced or eliminated by simple loading of the lateral column of the foot (Figure 4).

Capturing an impression model of a foot with maximal “twisting” of the forefoot into pronation follows a principle which assures reduction of pronation of the rearfoot. Essentially, pronation of the forefoot during digital scanning will produce a foot orthosis which promotes pronation of the forefoot which will block pronation of the rearfoot.

This observation is verified when evaluating the pathologic changes seen in adult acquired flatfoot (AAF). The severe frontal plane eversion of the rearfoot in AAF deformity is accompanied by equally severe inversion or supination of the forefoot. This acquired supination deformity of the forefoot in AAF is now recognized by foot and ankle surgeons as a primary contributor to residual rearfoot pronation and must be corrected in order to surgically realign the rearfoot.^{32,33}

Recognizing and reducing forefoot supination deformity is just as important in foot orthotic therapy as it is in reconstructive surgery. In relaxed position, either off weight-bearing or with weight-bearing, the patient with AAF will demonstrate significant forefoot supination (i.e., “supinatus”) deformity (Figure 5). This deformity is acquired and reducible, as opposed to a fixed congenital forefoot varus. Forefoot supinatus must be corrected with the orthotic casting technique in order for the orthosis to control rearfoot pronation.

Continued on page 80



Digital Scanning (from page 79)

In order to correct forefoot supinatus, the clinician must simultaneously pronate the forefoot on the rearfoot which is positioned in subtalar neutral. At the same time, the practitioner should apply a gentle plantarflexion force to the dorsal surface of the first metatarsal (Figures 6,7). Significant change in the shape of the scan or cast will take place as the forefoot is everted on the rearfoot and forefoot supination is reduced fully (Figure 8).

In contrast, leaving the forefoot supination deformity intact during the scanning process will produce an orthosis which will allow free, unrestricted pronation of the rearfoot. A simple comparison of two plaster impression casts of a patient with stage 2 AAF demonstrates the difference in rearfoot alignment when the supination deformity of the forefoot is corrected (Figure 6).

In summary, the non-weight-bearing condition allows optimal capture of the plantar foot contour to assure optimal position of the medial longitudinal arch, calcaneal width and inclination, as well as accurate forefoot to rearfoot alignment. Pronation of the forefoot on the rearfoot during the casting process will follow the twisted plate

mechanism of the human foot which will produce an orthosis which resists rearfoot pronation while limiting excessive sagittal plane motion across the midfoot joints. Taking a scan of the foot simply hanging in space will doom the resultant orthosis to failure as it will almost always maintain a supination deformity of

Continued on page 81

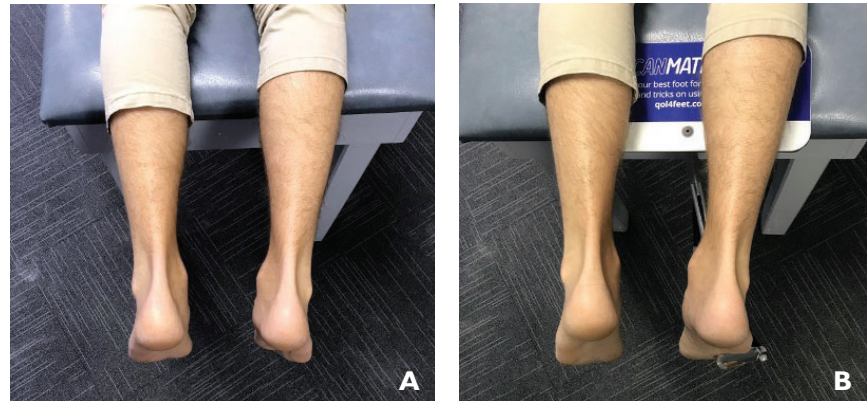


Figure 8: (A) Patient, prone position with un-corrected AAF deformity on right foot. (B) Optimal position for digital scanning: proper reduction of forefoot supination deformity.

Digital Scanning (from page 80)

the forefoot while allowing free, unrestricted pronation of the rearfoot. **PM**

Disclosure: Dr. Richie is the founder of Richie Technologies Inc., a company which markets ankle-foot orthotic devices.

References

- ¹ Chen RK, Y-a J, Wensman J, Shih A. Additive manufacturing of custom orthoses and prostheses—a review. *Addit Manuf.* 2016;12:77–89.
- ² Dombroski CE, Balsdon MER, Froats A. The use of a low cost 3D scanning and printing tool in the manufacture of custom-made foot orthoses: a preliminary study. *BMC Res Notes.* 2014;7(1):443.
- ³ Dombroski CE, Balsdon MER, Froats A. The use of a low cost 3D scanning and printing tool in the manufacture of custom-made foot orthoses: a preliminary study. *BMC Res Notes.* 2014;7(1):443.
- ⁴ Houston V, Mason C, Beattie A, LaBlanc K, Garbarini M, Lorenze E, et al. The VA-Cyberware lower limb prosthetics-orthotics optical laser digitizer. *J Rehabil Res Dev.* 1995;32(1):55–73.
- ⁵ Wand M, Adams B, Ovsjanikov M, Berner A, Bokeloh M, Jenke P, et al. Efficient reconstruction of nonrigid shape and motion from real-time 3D scanner data. *ACM Trans Graph.* 2009;28(2):15.
- ⁶ Chen RK, Y-a J, Wensman J, Shih A. Additive manufacturing of custom orthoses and prostheses—a review. *Addit Manuf.* 2016;12:77–89.
- ⁷ Y-a J, Plott J, Chen R, Wensman J, Shih A. Additive manufacturing of custom orthoses and prostheses—a review. *Procedia CIRP.* 2015;36:199–204.
- ⁸ Walbran M, Turner K, McDaid A. Customized 3D printed ankle-foot orthosis with adaptable carbon fibre composite spring joint. *Cogent Eng.* 2016;3(1):1227022.
- ⁹ Laughton C, Davis IM, Williams DS. A comparison of four methods of obtaining a negative impression of the foot. *J Am Podiatr Med Assoc.* 2002; 92(5):261–8.
- ¹⁰ Carroll M, Annabell M-E, Rome K. Reliability of capturing foot parameters using digital scanning and the neutral suspension casting technique. *J Foot Ankle Res.* 2011;4:9.
- ¹¹ Farhan M, Wang JZ, Bray P, Burns J, Cheng TL. Comparison of 3D scanning versus traditional methods of capturing foot and ankle morphology for the fabrication of orthoses: a systematic review. *J Foot Ankle Res.* 2021;7:2–11.
- ¹² Roberts A, Wales J, Smith H, Sampson CJ, Jones P, James M. A randomised controlled trial of laser scanning and casting for the construction of anklefoot orthoses. *Prosthetics Orthot Int.* 2016;40(2):253–61.
- ¹³ Telfer S, Gibson KS, Hennessy K, Steultjens MP, Woodburn J. Computer-aided design of customized foot orthoses: reproducibility and effect of method used to obtain foot shape. *Arch Phys Med Rehabil.* 2012;93(5):863–70.
- ¹⁴ Humble R, Stefanyshyn D. Orthotic comfort is related to kinematics, kinetics, and EMG in recreational runners. *Med Sci Sports Exerc.* 2003;35:1710–9.
- ¹⁵ Root M, Weed J, Orien W: *Neutral Position Casting Techniques* Los Angeles: Clinical Biomechanic Corporation; 1971.
- ¹⁶ Losito J: *Impression Casting Techniques*. In *Clinical Biomechanic of the Lower Extremities*. Edited by: Valmassey R. St Louis: CV Mosby; 1996:280-294.
- ¹⁷ Harradine P, Bevan L: A review of the theoretical unified approach to podiatric biomechanics in relation to orthoses theory. *J Am Podiatr Med Assoc* 2009, 99:317-325.

Continued on page 82



Digital Scanning (from page 81)

¹⁸ Root J, Richie D. A comparison of negative casting techniques used for the fabrication of custom ankle foot orthoses. *Podiatry Management* Sept 2007; 129-136.

¹⁹ Tsung BY, Zhang M, Fan YB, Boone DA. Quantitative comparison of plantar foot shapes under different weight-bearing conditions. *Journal of Rehabilitation Research and Development* Vol. 40, No. 6, 2003; 517-526.

²⁰ Root M, Weed J, Orien W: *Neutral Position Casting Techniques* Los Angeles: Clinical Biomechanic Corporation; 1971.

²¹ Chuter V, Payne C, Miller K: Variability of Neutral-Position Casting of the Foot. *J Am Podiatr Med Assoc* 2003, 93:1-5.

²² Burns J, Hartshorne P, Crosbie J: Reliable casting of pes cavus to minimize errors in custom orthosis fabrication. *Australas J Podiatric Med* 2005, 39:91-94.

²³ Landorf K, Keenan A, Rushworth L: Foot Orthosis Prescription Habits of Australian and New Zealand Podiatric Physicians. *J Am Podiatr Med Assoc* 1991, 91:175-183.

²⁴ Okita N, Meyers SA, Challis JH, Sharkey NA: Midtarsal joint locking: new

perspectives on an old paradigm. *J Orthop Res* 2014, 32(1):110-115.

²⁵ Nester CJ, Jarvis HL, Jones RK, Bowden PD, Anmin L. Movement of the human foot in 100 pain free individuals aged 18-45: implications for understanding normal foot function. *Journal of Foot and Ankle Research* 2014, 7:51.

²⁶ Phillips, RD; Phillips, RL: Quantitative analysis of the locking position of the midtarsal joint. *J. Am. Podiatry Assoc.* 73(10):518-522, 1983.

²⁷ Gatt A, Chockalingam N, Chevalier TL. Sagittal plane kinematics of the foot during passive ankle dorsiflexion. *Prosthet Orthot Int.* 2011;35:425-31.

²⁸ Bojsen-Møller F. Calcaneocuboid joint and stability of the longitudinal arch of the foot at high and low gear push off. *J Anat* 1979;129:165.

²⁹ Steindler A. The supinatory compensatory torsion of the forefoot in pes valgus. *J Bone Joint Surg Am.* 1929 April 01;(11) 2: 272-276.

³⁰ MacConaill MA. The postural mechanism of the human foot. *Proceedings of the Royal Irish Academy* 1944-45; 50B, 265-278.

³¹ Sarrafian SK, Kelikian AS. Development of the foot and ankle in: Keliki-

an AS, Editor. *Sarrafian's Anatomy of the Foot and Ankle*. Third Edition. Philadelphia:Wolters Kluwer, 2011., p3-39.

³² Bluman EM, Title CI, Myerson MS. Posterior tibial tendon rupture: a refined classification system. *Foot Ankle Clin.* 2007;12(2):233-249.

³³ Johnson J, Sangeorzan B, de Cesar Netto C, Deland J. et al. Consensus on indications for medial cuneiform opening wedge (Cotton) osteotomy in the treatment of progressive collapsing foot deformity. *Foot & Ankle International*; Oct 2020, Vol. 41 Issue 10, p1289-1291.



Dr. Richie is an Associate Clinical Professor at the California School of Podiatric Medicine at Samuel Merritt University. He is a Fellow and Past President of the American Academy of Podiatric Sports Medicine. Dr.

Richie is the author of a new book titled "*Pathomechanics of Common Foot Disorders*" available at <https://www.springer.com/us/book/9783030542009>.